

Grade 1 Shoulder Separation

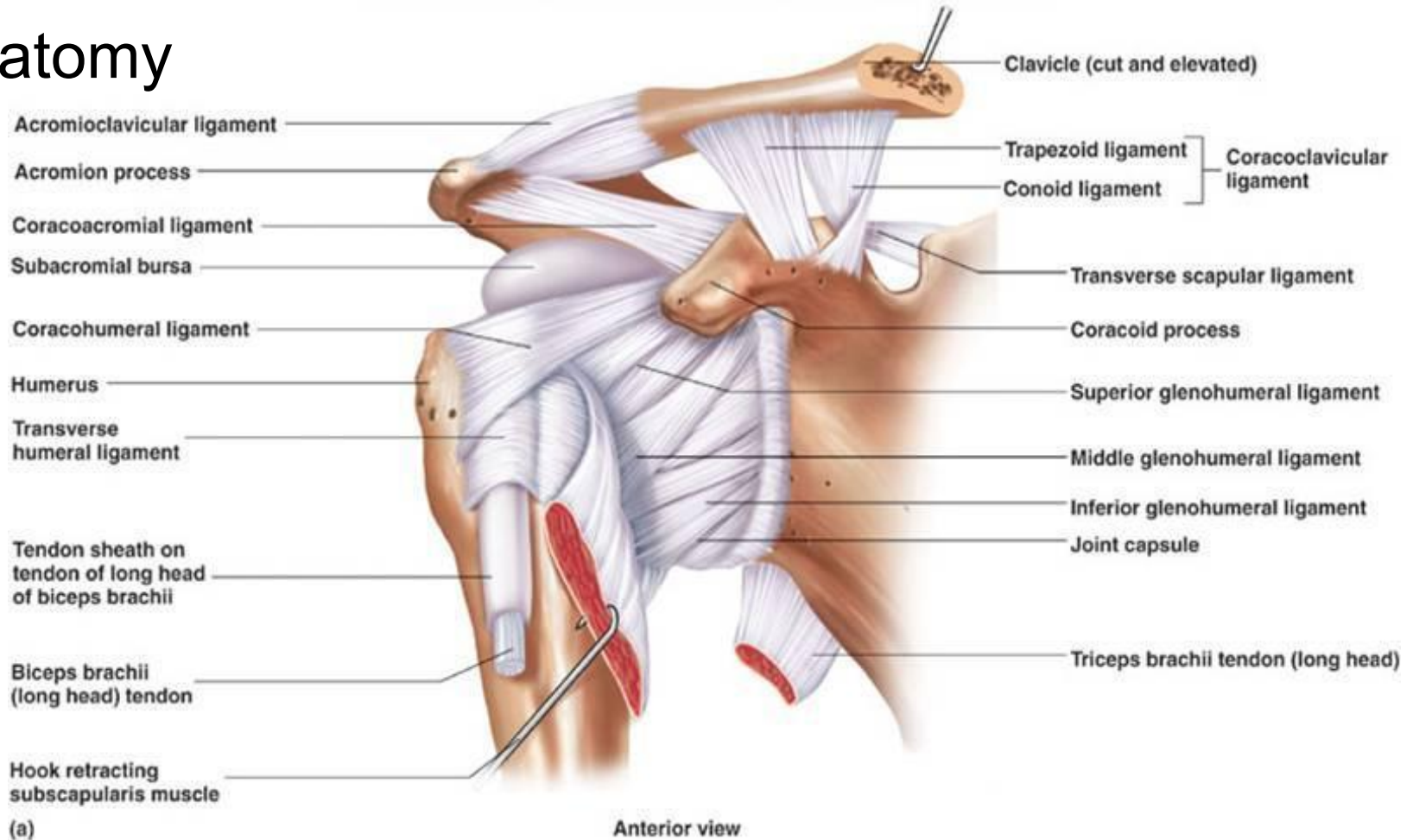
A Common UE MSK Dysfunction

Andrew Taylor Still

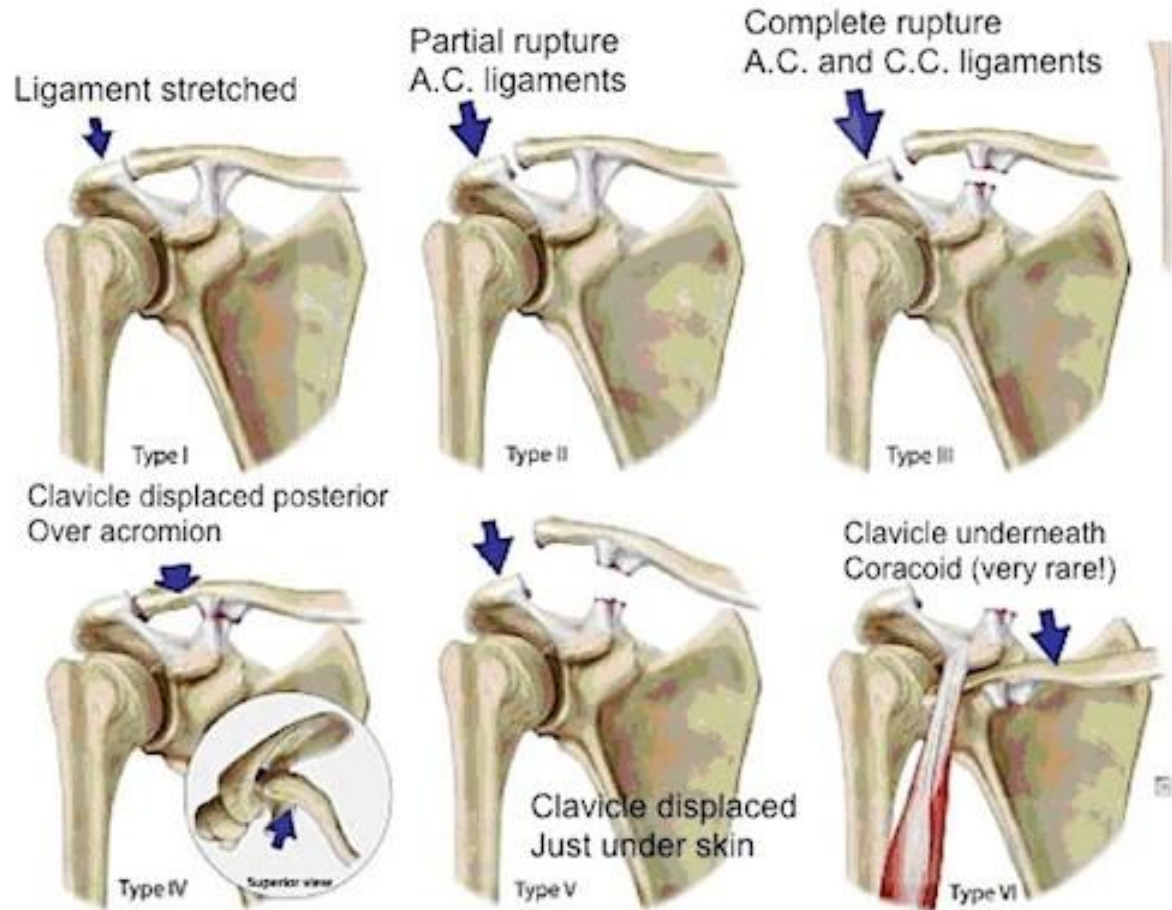
*You begin with anatomy, and you end with anatomy,
a knowledge of anatomy is all you want or need . . .*

-- Philosophy of Osteopathy

Anatomy



Grades of AC Sprain



Discussion

- Presentation neck/shoulder pain
- History impact, fall, exertion, RSI
- Tender points trapezius, deltoid insertion, serratus, pectorals
- Muscle testing medial deltoid: beware patient recruitment of other groups
- OMM articulatory, HVLA, BLT
- Exercises fwd, side, back, for 2-3 weeks +/-weight, PALM FACING
- Taping from point of scapula, lift skin over pecs, apply (support AC)

CREDIT AND THANKS TO:

Dr. Edward P. Jastram III, DC

Dr. David W. Leaf, DC